

Patient Name: Mixed, Example	Referring Physician: Geoff Refman
Date of Study: 2010-01-01 Outpatient	8700 Beverly Blvd. NT LL A047 Los Angeles, CA, 90048
ID Number: 98700001 Acct#:1111222233333	Fax (310) 555-2233 Phone (310) 555-1234
Age: 62 Sex: F DOB: 1948-01-01	

- Reason: coronary artery disease, shortness of breath
- Symptom: shortness of breath
- History: prior myocardial infarction (12/7/1999), angiogram (5/2009), stent of the right coronary artery (5/2009) Cath at Glendale Mem. Hosp in 2009: RCA stented, LAD 100%
- Risk factors: hypercholesterolemia, diabetes, family history of coronary disease
- Medications: beta blockers, oral diabetic agent, Plavix
- Height: 66 in. Weight: 188 lbs. Body Mass Index (BMI): 30.3

Adenosine Stress ECG Results:

- Type: Walking Adenosine
- Protocol duration = 07:30 minutes; Rest HR 77; Peak HR 123
- Blood Pressure: Rest: 153/90; Stress: 124/80
- Resting ECG: Low voltage QRS
- Stress ECG: no ST segment depression

Nuclear Results:

- Sestamibi (Same day) gated SPECT [stress/rest sestamibi (Prone and Supine)]
- Technical quality: excellent
- **Myocardial Perfusion: Total perfusion defect 24% myocardium (14% reversible, 10% fixed)**

Vessel	Reversible	Nonreversible
LAD	large (anterior/septal/inferior)	small to medium (lateral/apical)
LV enlargement: no; Visual TID: no; TID Ratio 1.25		
- **Myocardial Function:**

	LVEF	EDVi
Rest	44%	48 ml/ml ²
Post Stress (63 min after)	40%	48 ml/ml ²

Left ventricular wall motion demonstrated akinesis in the apical wall and moderate hypokinesis in the anterior, septal, inferior and lateral walls.

Conclusion: Clinical Response Nondiagnostic **Perfusion** Abnormal (Reversible and Nonreversible)
ECG Response Nonischemic **Function** Abnormal rest, no change after stress

These test results indicate a high (>90%) likelihood for the presence of jeopardized myocardium.

- LAD: a small to medium sized nonreversible defect involving the lateral and apical walls, with an adjacent large severe reversible defect in the anterior, septal and inferior walls.

The severity of the anterior and inferior perfusion defects suggests that the LAD stenosis is critical (>90%).

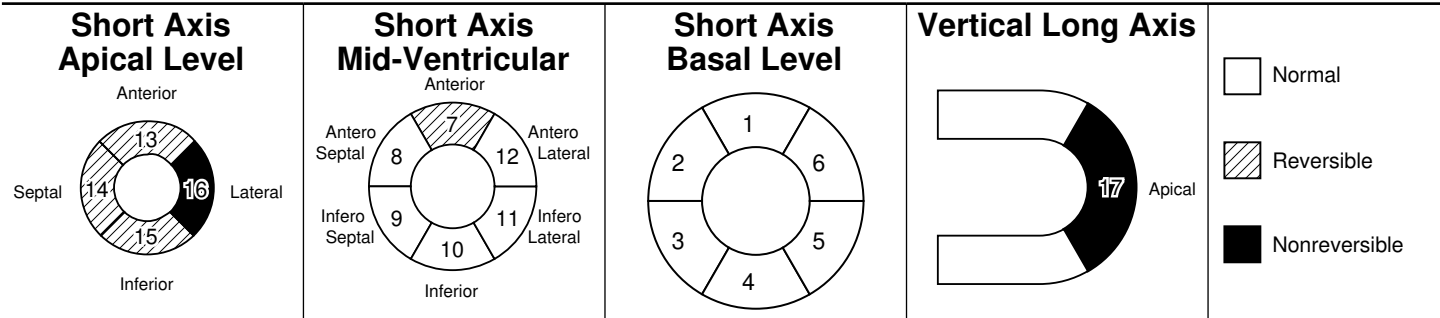
The results were discussed with Dr. Refman

Sean W Hayes


Sean Hayes, M.D.

Stress ECG monitored and interpreted by Geoff Refman

Patient Name: **Mixed, Example** Referring Physician: **Geoff Refman**
 Date of Study: **2010-01-01** Outpatient 8700 Beverly Blvd.
 ID Number: **98700001** Acct#: **1111222233333** NT LL A047
 Age: **62** Sex: **F** DOB: **1948-01-01** Los Angeles, CA, 90048
 Fax (310) 555-2233 Phone (310) 555-1234



	S R		S R		S R		S R		
13. Anterior	3	1	7. Anterior	2	0	1. Anterior	0	0	0 = Normal 1 = Mildly reduced Equivocal 2 = Moderately Reduced 3 = Severely Reduced 4 = Absent Uptake S = Stress R = Rest
14. Septal	2	1	8. AnteroSeptal	0	0	2. AnteroSeptal	0	0	
15. Inferior	3	1	9. InferoSeptal	0	0	3. InferoSeptal	0	0	
16. Lateral	3	2	10. Inferior	0	0	4. Inferior	0	0	
			11. InferoLateral	0	0	5. InferoLateral	0	0	
			12. AnteroLateral	0	0	6. AnteroLateral	0	0	
						17. Apical	3	2	



Date of study	Results	%Total defects	%Reversible	%Fixed	Stress Type
2010-01-01	Abnormal	24%	14%	10%	Adenosine

Adenosine (60.2 mg IV) (same day protocol) gated myocardial perfusion SPECT using Tc-99m sestamibi (35.4 mCi IV) at stress and (8.5 mCi IV) at rest was performed using the rest/stress sequence. Sestamibi SPECT was performed in the supine and prone positions.

Findings:

Vessel	Reversible	Nonreversible
LAD	large (anterior/septal/inferior)	small to medium (lateral/apical)

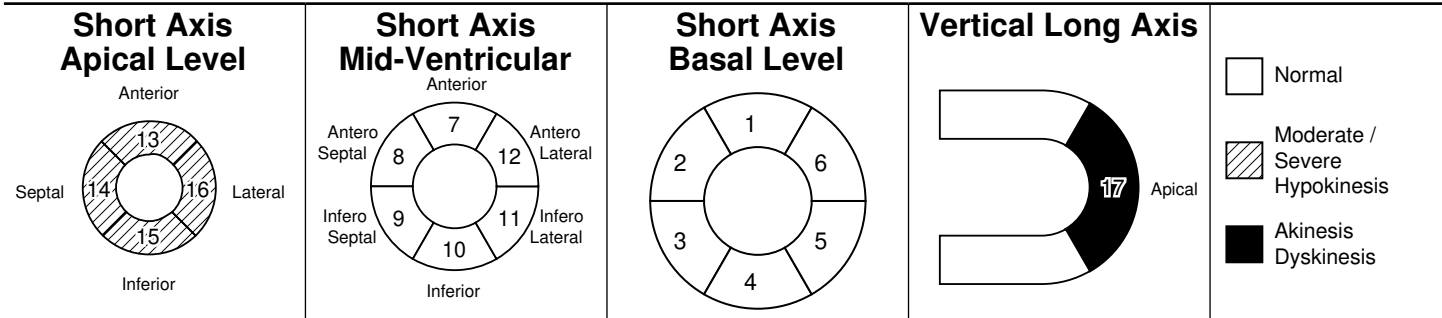
Myocardial perfusion test result: definitely abnormal with both reversible and nonreversible defects.

Sean W Hayes

Sean Hayes, M.D.

%Myocardium		%Reversible		%Fixed		Vessel Descriptions
Normal/Equivocal	0-4%	Normal	0-2%	Normal/Equivocal	0-4%	RCA (Right Coronary Artery)
Mild	5-9%	Mild	3-5%	Mild	5-9%	LAD (Left Anterior Descending)
Moderate	10-14%	Moderate	6-9%	Moderate	10-14%	LCX (Left Circumflex)
Severe	>14%	Severe	>10%	Severe	>14%	DIAG (Diagonal)

Patient Name: **Mixed, Example** Referring Physician: **Geoff Refman**
 Date of Study: **2010-01-01 Outpatient** 8700 Beverly Blvd.
 ID Number: **98700001 Acct#:1111222233333** NT LL A047
 Age: **62** Sex: **F** DOB: **1948-01-01** Los Angeles, CA, 90048
 Fax (310) 555-2233 Phone (310) 555-1234



	S	R	S	R	S	R	S	R	
13. Anterior	2	2	7. Anterior	0	0	1. Anterior	0	0	0 = Normal 1 = Mild Hypokinesia 2 = Moderate Hypokinesia 3 = Severe Hypokinesia 4 = Akinesis 5 = Dyskinesia S = Stress R = Rest
			8. AnteroSeptal	0	0	2. AnteroSeptal	0	0	
14. Septal	2	2	9. InferoSeptal	0	0	3. InferoSeptal	0	0	
15. Inferior	2	2	10. Inferior	0	0	4. Inferior	0	0	
			11. InferoLateral	0	0	5. InferoLateral	0	0	
16. Lateral	2	2	12. AnteroLateral	0	0	6. AnteroLateral	0	0	
						17. Apical	4	4	

Date of study	Rest			Stress			TID ratio
	EF	EDV	EDVi	EF	EDV	EDVi	
2010-01-01	44%	93 ml	48 ml/m2	40%	94 ml	48 ml/m2	1.25

Left ventricular wall motion demonstrated akinesia in the apical wall and moderate hypokinesia in the anterior, septal, inferior and lateral walls.

Wall motion results: definitely abnormal; abnormal rest, no change after stress

Sean W Hayes

Sean Hayes, M.D.

	Men	Women
Normal EF (mean - 2sd)	>42%	>50%
Severely Reduced EF	<30%	<35%
Normal EDV (mean + 2sd)	<150 ml	<103 ml
Normal EDVi (mean + 2sd)	<76 ml/m2	<61 ml/m2

Sharir et al., J. Nucl Cardiol 2006;13:495-506

EF	Ejection Fraction
EDV	End Diastolic Volume
EDVi	End Diastolic Volume index
TID	Transient Ischemic Dilation



Adenosine Stress Electrocardiography

Patient Name: Mixed, Example	Referring Physician: Geoff Refman
Date of Study: 2010-01-01 Outpatient	8700 Beverly Blvd.
ID Number: 98700001 Acct#:1111222233333	NT LL A047
Age: 62 Sex: F DOB: 1948-01-01	Los Angeles, CA, 90048
	Fax (310) 555-2233 Phone (310) 555-1234

A total of 60.2 mg of Adenosine was infused. A standard 12 LEAD ELECTROCARDIOGRAM was recorded in the supine position with continuous ECG monitoring throughout infusion and recovery. Additionally, 12 LEAD ELECTROCARDIOGRAMS were recorded every minute.

Adenosine Physiology

Resting Hemodynamics	Heart Rate: 77	Blood Pressure: 153/90
Arrhythmia	None	

Stress							Recovery		
Minutes	HR	BP	MPH	Grade	METS	Comments	HR	BP	Comments
1	98					flush, chest pain, dyspnea	101		
2	112	136/84					85	164/87	
3	121						75		symptoms resolved
4	123	124/80				moderate chest pain	83	169/95	pt instructed to resume BP meds
5	118						73		

Electrocardiogram

Rest	Low voltage QRS
Stress	
V5	Maximum Abnormality: None
AVF	Maximum Abnormality: None

Date of study	Stress	Duration	Peak HR	Clinical	ECG
2010-01-01	Adenosine	07:30	123(78 %)	Nondiagnostic	Nonischemic

Impression

Clinical response to Adenosine: Nondiagnostic with chest discomfort
 ECG response to Adenosine: Nonischemic
 Stress ECG monitored and interpreted by Geoff Refman

Sean W Hayes

Sean Hayes, M.D.