

Patient Name: Ishemia, Example	Referring Physician: Geoff Refman
Date of Study: 2010-01-01 Outpatient	8700 Beverly Blvd. NT LL A047 Los Angeles, CA, 90048
ID Number: 98700002 Acct#:123456789012	Fax (310) 555-2233 Phone (310) 555-1234
Age: 71 Sex: M DOB: 1939-01-01	

- Reason: coronary artery disease
- Symptom: shortness of breath, typical chest pain
- History: prior bypass surgery (9/2003)
- Risk factors: hypercholesterolemia, hypertension
- Medications: ARBs, aspirin, cholesterol medications, HMG CoA reductase inhibitor
- Height: 69 in. Weight: 158 lbs. Body Mass Index (BMI): 23.3

Exercise Stress ECG Results:

- Type: Bruce
- Exercise duration = 12:00 minutes; Rest HR 52; Peak HR 130 (87% of maximum-predicted)
- Blood Pressure: Rest: 150/80; Stress: 190/80
- Symptom during test: chest discomfort occurred
- Reason for termination of exercise: chest pain
- Resting ECG: sinus bradycardia, inferior myocardial infarction and left axis deviation
- Stress ECG: no ST segment depression

Nuclear Results:

- Sestamibi (Same day) gated SPECT [stress/rest sestamibi (Prone and Supine)]
- Technical quality: good
- **Myocardial Perfusion: Total perfusion defect 12% myocardium (12% reversible, 0% fixed)**

Vessel	Reversible
LAD	large (anterior/anteroseptal)
LV enlargement: yes; Visual TID: no; TID Ratio 1.04	

- **Myocardial Function:**

	LVEF	EDVi
Rest	53%	85 ml/ml2
Post Stress (10 min after)	48%	90 ml/ml2

Left ventricular wall motion demonstrated moderate hypokinesis in the septal wall. Worsening of wall motion in the anterior wall was seen in the exercise stress images.

Conclusion: Clinical Response Ischemic	Perfusion Prob abnormal (Reversible)
ECG Response Ischemic (S-T depression)	Function Abnormal rest, worse after stress

These test results indicate a high (>90%) likelihood for the presence of exercise induced ischemia.

- LAD: a large reversible defect in the anterior and anteroseptal walls.

The left ventricle is enlarged. these defects are probably in the distribution of a diagonal and septal perforator.

If this patient has had a graft to his left anterior descending coronary artery, it is most likely open since the apex and distal septum have normal perfusion.

Compared to the previous study of Nov 11, 2009 (performed a California Heart Institute) and allowing for changes in imaging technique, there has been no significant change.



John Friedman M.D.



Daniel S. Berman M.D.

Stress ECG monitored and interpreted by Geoff Refman

Important Warning: This information is intended for the use of the person or entity to which it is addressed and may contain information that is privileged and confidential, the disclosure of which is governed by applicable law. If the reader of this information is not the intended recipient, or the employee or agent responsible to deliver it to the intended recipient, you are hereby notified that any dissemination, distribution or copy of this information is STRICTLY PROHIBITED. If you have received this information in error, please notify us immediately (310) 423-8000 and destroy the related message. Thank you for your cooperation.

Patient Name: **Ishemia, Example**

 Referring Physician: **Geoff Refman**

 Date of Study: **2010-01-01** Outpatient

 ID Number: **98700002** Acct#: **123456789012**

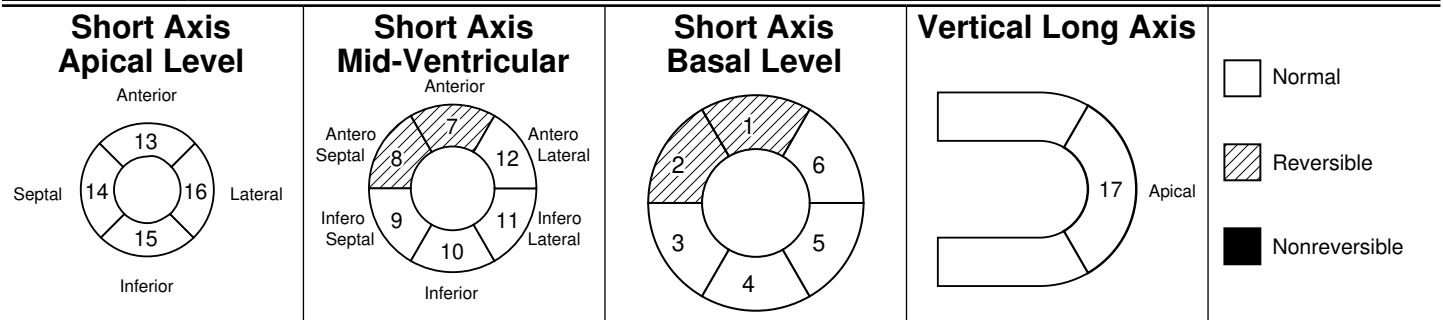
 Age: **71** Sex: **M** DOB: **1939-01-01**

8700 Beverly Blvd.

NT LL A047

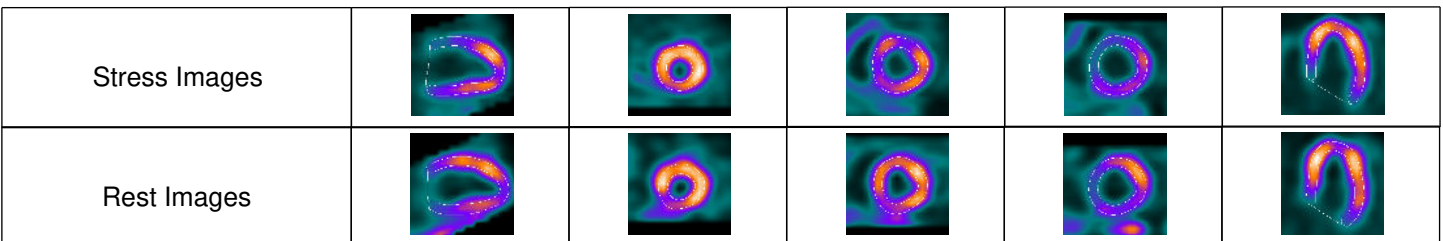
Los Angeles, CA, 90048

Fax (310) 555-2233 Phone (310) 555-1234



	S	R	S	R	S	R	S	R
13. Anterior	0	0	7. Anterior	2	0	1. Anterior	2	0
			8. AnteroSeptal	2	0	2. AnteroSeptal	2	0
14. Septal	0	0	9. InferoSeptal	0	0	3. InferoSeptal	0	0
15. Inferior	0	0	10. Inferior	0	0	4. Inferior	0	0
			11. InferoLateral	0	0	5. InferoLateral	0	0
16. Lateral	0	0	12. AnteroLateral	0	0	6. AnteroLateral	0	0
						17. Apical	0	0

0 = Normal
 1 = Mildly reduced Equivocal
 2 = Moderately Reduced
 3 = Severely Reduced
 4 = Absent Uptake
 S = Stress R = Rest



Date of study	Results	%Total defects	%Reversible	%Fixed	Stress Type
2010-01-01	Prob abnormal	12%	12%	0%	Exercise

Exercise (same day protocol) gated myocardial perfusion SPECT using Tc-99m sestamibi (36.0 mCi IV) at stress and (8.2 mCi IV) at rest was performed using the rest/stress sequence. Sestamibi SPECT was performed in the supine and prone positions.

Findings:

Vessel **Reversible**
 LAD large (anterior/anteroseptal)

Myocardial perfusion test result: probably abnormal with reversible defect.



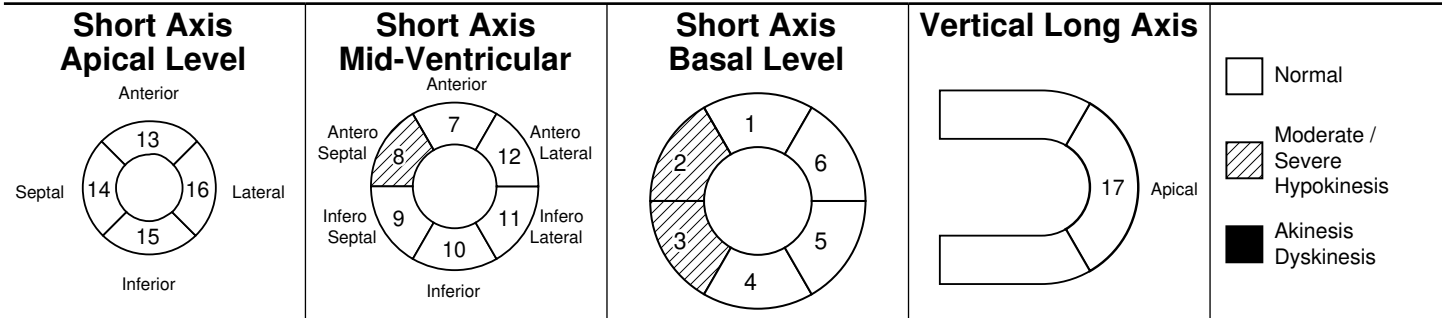
John Friedman M.D.



Daniel S. Berman M.D.

%Myocardium		%Reversible		%Fixed		Vessel Descriptions
Normal/Equivocal	0-4%	Normal	0-2%	Normal/Equivocal	0-4%	RCA (Right Coronary Artery)
Mild	5-9%	Mild	3-5%	Mild	5-9%	LAD (Left Anterior Descending)
Moderate	10-14%	Moderate	6-9%	Moderate	10-14%	LCX (Left Circumflex)
Severe	>14%	Severe	>10%	Severe	>14%	DIAG (Diagonal)

Patient Name: **Ishemia, Example** Referring Physician: **Geoff Refman**
 Date of Study: **2010-01-01 Outpatient** 8700 Beverly Blvd.
 ID Number: **98700002 Acct#:123456789012** NT LL A047
 Age: **71** Sex: **M** DOB:**1939-01-01** Los Angeles, CA, 90048
 Fax (310) 555-2233 Phone (310) 555-1234



	S R		S R		S R		S R		
13. Anterior	0	0	7. Anterior	1	0	1. Anterior	1	0	0 = Normal 1 = Mild Hypokinesia 2 = Moderate Hypokinesia 3 = Severe Hypokinesia 4 = Akinesis 5 = Dyskinesia S = Stress R = Rest
			8. AnteroSeptal	2	2	2. AnteroSeptal	2	2	
14. Septal	0	0	9. InferoSeptal	0	0	3. InferoSeptal	2	2	
15. Inferior	0	0	10. Inferior	0	0	4. Inferior	0	0	
			11. InferoLateral	0	0	5. InferoLateral	0	0	
16. Lateral	0	0	12. AnteroLateral	0	0	6. AnteroLateral	0	0	
						17. Apical	0	0	

Date of study	Rest			Stress			TID ratio
	EF	EDV	EDVi	EF	EDV	EDVi	
2010-01-01	53%	159 ml	85 ml/m2	48%	169 ml	90 ml/m2	1.04

Left ventricular wall motion demonstrated moderate hypokinesia in the septal wall. Worsening of wall motion in the anterior wall was seen in the exercise stress images.

Wall motion results: probably abnormal; abnormal rest, worse after stress

John Friedman

John Friedman M.D.

Daniel S. Berman

Daniel S. Berman M.D.

	Men	Women
Normal EF (mean - 2sd)	>42%	>50%
Severely Reduced EF	<30%	<35%
Normal EDV (mean + 2sd)	<150 ml	<103 ml
Normal EDVi (mean + 2sd)	<76 ml/m2	<61 ml/m2

Sharir et al., J. Nucl Cardiol 2006;13:495-506

EF	Ejection Fraction
EDV	End Diastolic Volume
EDVi	End Diastolic Volume index
TID	Transient Ischemic Dilation

Patient Name: Ishemia, Example	Referring Physician: Geoff Refman
Date of Study: 2010-01-01 Outpatient	8700 Beverly Blvd. NT LL A047 Los Angeles, CA, 90048
ID Number: 98700002 Acct#:123456789012	Fax (310) 555-2233 Phone (310) 555-1234
Age: 71 Sex: M DOB: 1939-01-01	

A standard 12 LEAD ELECTROCARDIOGRAM was recorded with continuous ECG monitoring throughout exercise and recovery. Additionally, 12 LEAD ELECTROCARDIOGRAMS were recorded every minute.

Stress Physiology

Resting Hemodynamics	Heart Rate: 52 Blood Pressure: 150/80
Exertional Hypotension	No
Arrhythmia	Occasional PVC's during exercise with couplets
Reason for termination	chest pain

Stress							Recovery		
Minutes	HR	BP	MPH	Grade	METS	Comments	HR	BP	Comments
1	60		1.7	10.0 %	2.0		115	180/90	
2	83		1.7	10.0 %	3.5		100		8/10 chest discomfort
3	85	170/80	1.7	10.0 %	5.0		84		
4	96		2.5	12.0 %	6.0		75	160/80	2/10 chest discomfort
5	98		2.5	12.0 %	6.5		73		
6	96	175/80	2.5	12.0 %	7.0		70		
7	106		3.4	14.0 %	8.0		73	150/80	
8	106		3.4	14.0 %	9.0				
9	106	175/80	3.4	14.0 %	10.0				
10	117		4.2	16.0 %	11.0	chest discomfort 7/10			
11	121		4.2	16.0 %	12.0				
12	130	190/80	4.2	16.0 %	13.0	chest discomfort 8/10			

Electrocardiogram

Rest	sinus bradycardia, inferior myocardial infarction and left axis deviation
Stress	
V5	Maximum Abnormality: --1.7mm horizontal ECG First became Abnormal: Exercise minute 10
AVF	Maximum Abnormality: --1.9mm horizontal ECG First became Abnormal: Exercise minute 10

Date of study	Stress	Duration	Peak HR	Clinical	ECG
2010-01-01	Exercise	12:00	130(87 %)	Ischemic	Ischemic (S-T depression)

Impression

Clinical response to Exercise: Ischemic with chest discomfort
ECG response to Exercise: Ischemic due to the development of significant ST segment depression
Stress ECG monitored and interpreted by Geoff Refman


John Friedman M.D.


Daniel S. Berman M.D.