

Patient Name: <b>Infarct, Example</b>	Referring Physician: <b>Geoff Refman</b>
Date of Study: <b>2010-01-01 Inpatient Rm: 0001</b>	8700 Beverly Blvd. NT LL A047 Los Angeles, CA, 90048
ID Number: <b>98700003 Acct#:1234567890123</b>	Fax (310) 555-2233 Phone (310) 555-1234
Age: <b>67</b> Sex: <b>M</b> DOB: <b>1943-01-01</b>	

- Reason: chest pain, coronary artery disease
- Symptom: atypical chest pain
- History: prior PTCA (1999), bypass surgery (1995)
- Risk factors: hypercholesterolemia, hypertension
- Medications: ACE inhibitor, aspirin, beta blockers, digoxin, diuretic, HMG CoA reductase inhibitor
- Height: 70 in. Weight: 174 lbs. Body Mass Index (BMI): 25

**Adenosine Stress ECG Results:**

- Protocol duration = 06:15 minutes; Rest HR 60; Peak HR 66
- Blood Pressure: Rest: 96/63; Stress: 91/51
- Resting ECG: paced atrial rhythm
- Stress ECG: no ST segment depression

**Nuclear Results:**

- Sestamibi (Same day) gated SPECT [stress/rest sestamibi (Prone and Supine)]
- Technical quality: excellent
- **Myocardial Perfusion: Total perfusion defect 47% myocardium (0% reversible, 47% fixed)**

<b>Vessel</b>	<b>Nonreversible</b>
LAD	large (anterior/septal/inferior/lateral/apical)
LV enlargement: yes; Visual TID: no; TID Ratio 1.10	

- **Myocardial Function:**

	LVEF	EDVi
Rest	32%	132 ml/ml2
Post Stress (104 min after)	26%	147 ml/ml2

Left ventricular wall motion demonstrated dyskinesia in the septal wall and akinesis in the anterior, inferior, lateral and apical walls.

<b>Conclusion: Clinical Response</b> Equivocal	<b>Perfusion</b> Abnormal (Nonreversible)
<b>ECG Response</b> Nondiagnostic (Paced)	<b>Function</b> Abnormal rest, no change after stress

These test results indicate a low (<10%) likelihood for the presence of jeopardized myocardium.

- LAD: a large nonreversible defect involving the anterior, septal, inferior, lateral and apical walls. The left ventricle is markedly enlarged and LV function is severely decreased.

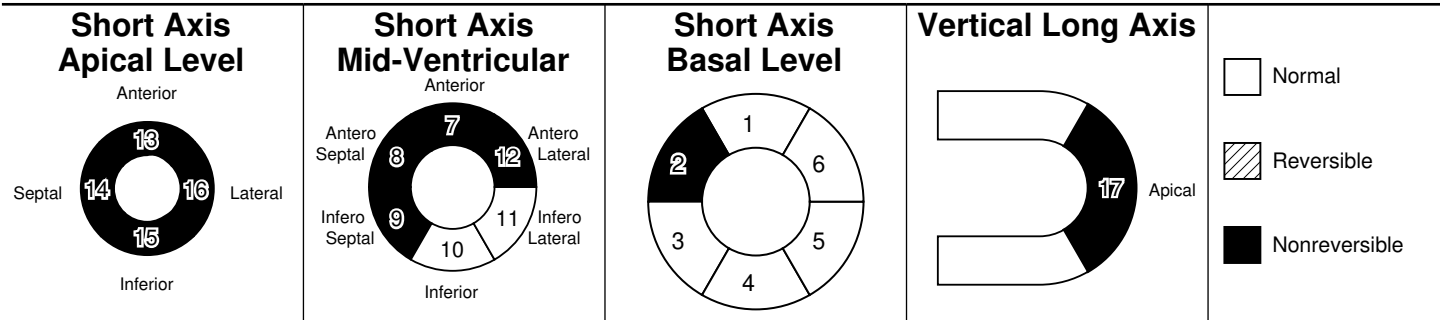
Compared to the previous adenosine myocardial perfusion study of September 25, 2007, there has been no significant change in myocardial perfusion or function.

*Sean W Hayes*

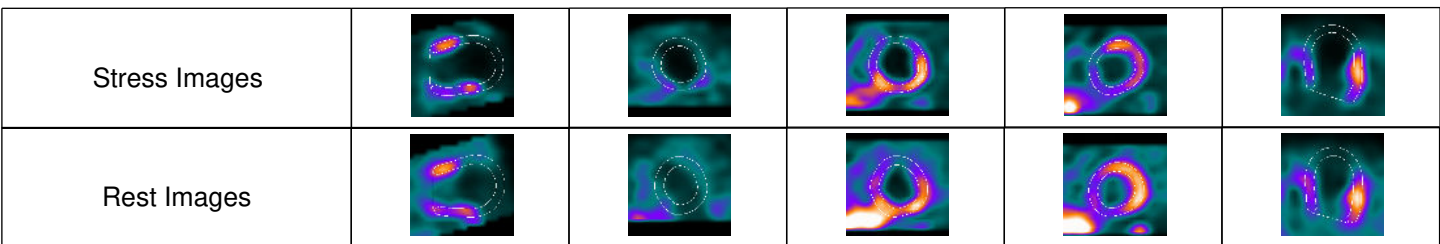
Sean Hayes, M.D.

Stress ECG monitored and interpreted by Geoff Refman

Patient Name: **Infarct, Example** Referring Physician: **Geoff Refman**  
 Date of Study: **2010-01-01** Inpatient Rm: **0001** 8700 Beverly Blvd.  
 ID Number: **98700003** Acct#: **1234567890123** NT LL A047  
 Los Angeles, CA, 90048  
 Age: **67** Sex: **M** DOB: **1943-01-01** Fax (310) 555-2233 Phone (310) 555-1234



	S	R	S	R	S	R	S	R	
<b>13. Anterior</b>	4	4	<b>7. Anterior</b>	3	3	<b>1. Anterior</b>	0	0	0 = Normal 1 = Mildly reduced Equivocal 2 = Moderately Reduced 3 = Severely Reduced 4 = Absent Uptake S = Stress R = Rest
<b>14. Septal</b>	4	4	<b>8. AnteroSeptal</b>	3	3	<b>2. AnteroSeptal</b>	2	2	
<b>15. Inferior</b>	4	4	<b>9. InferoSeptal</b>	2	2	<b>3. InferoSeptal</b>	0	0	
<b>16. Lateral</b>	4	4	<b>10. Inferior</b>	0	0	<b>4. Inferior</b>	0	0	
			<b>11. InferoLateral</b>	0	0	<b>5. InferoLateral</b>	0	0	
			<b>12. AnteroLateral</b>	2	2	<b>6. AnteroLateral</b>	0	0	
						<b>17. Apical</b>	4	4	



Date of study	Results	%Total defects	%Reversible	%Fixed	Stress Type
2010-01-01	Abnormal	47%	0%	47%	Adenosine
2007-09-25	Abnormal	47%	0%	47%	Adenosine

Adenosine (55.3 mg IV) (same day protocol) gated myocardial perfusion SPECT using Tc-99m sestamibi (35.7 mCi IV) at stress and (8.0 mCi IV) at rest was performed using the rest/stress sequence. Sestamibi SPECT was performed in the supine and prone positions.

**Findings:**

**Vessel Nonreversible**  
LAD large (anterior/septal/inferior/lateral/apical)

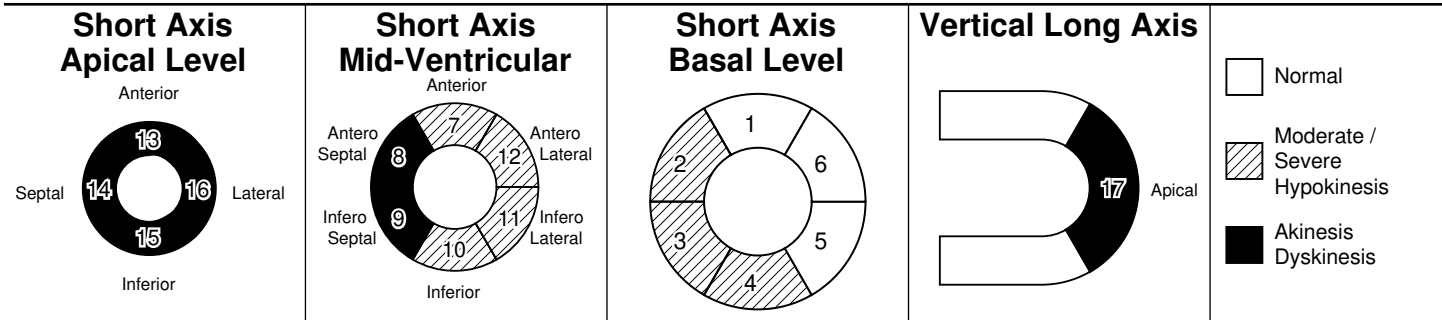
**Myocardial perfusion test result:** definitely abnormal with nonreversible defect.

*Sean W Hayes*

Sean Hayes, M.D.

%Myocardium		%Reversible		%Fixed		Vessel Descriptions
Normal/Equivocal	0-4%	Normal	0-2%	Normal/Equivocal	0-4%	RCA (Right Coronary Artery)
Mild	5-9%	Mild	3-5%	Mild	5-9%	LAD (Left Anterior Descending)
Moderate	10-14%	Moderate	6-9%	Moderate	10-14%	LCX (Left Circumflex)
Severe	>14%	Severe	>10%	Severe	>14%	DIAG (Diagonal)

Patient Name: **Infarct, Example** Referring Physician: **Geoff Refman**  
 Date of Study: **2010-01-01** Inpatient Rm: **0001** 8700 Beverly Blvd.  
 ID Number: **98700003** Acct#: **1234567890123** NT LL A047  
 Age: **67** Sex: **M** DOB: **1943-01-01** Los Angeles, CA, 90048  
 Fax (310) 555-2233 Phone (310) 555-1234




	S		R		S		R		S		R		
<b>13. Anterior</b>	4	4	<b>7. Anterior</b>	3	3	<b>1. Anterior</b>	0	0					0 = Normal 1 = Mild Hypokinesia 2 = Moderate Hypokinesia 3 = Severe Hypokinesia 4 = Akinesis 5 = Dyskinesia S = Stress R = Rest
			<b>8. AnteroSeptal</b>	5	5	<b>2. AnteroSeptal</b>	3	3					
<b>14. Septal</b>	5	5	<b>9. InferoSeptal</b>	5	5	<b>3. InferoSeptal</b>	3	3	<b>17. Apical</b>	4	4		
<b>15. Inferior</b>	4	4	<b>10. Inferior</b>	2	2	<b>4. Inferior</b>	2	2					
			<b>11. InferoLateral</b>	2	2	<b>5. InferoLateral</b>	0	0					
<b>16. Lateral</b>	4	4	<b>12. AnteroLateral</b>	2	2	<b>6. AnteroLateral</b>	0	0					

Date of study	Rest			Stress			TID ratio
	EF	EDV	EDVi	EF	EDV	EDVi	
2010-01-01	32%	260 ml	132 ml/m2	26%	290 ml	147 ml/m2	1.10
2007-09-25	28%	310 ml	160 ml/m2	24%	296 ml	153 ml/m2	0.94

Left ventricular wall motion demonstrated dyskinesia in the septal wall and akinesis in the anterior, inferior, lateral and apical walls.

**Wall motion results:** definitely abnormal; abnormal rest, no change after stress



Sean Hayes, M.D.

	Men	Women
Normal EF (mean - 2sd)	>42%	>50%
Severely Reduced EF	<30%	<35%
Normal EDV (mean + 2sd)	<150 ml	<103 ml
Normal EDVi (mean + 2sd)	<76 ml/m2	<61 ml/m2

Sharir et al., J. Nucl Cardiol 2006;13:495-506

EF	Ejection Fraction
EDV	End Diastolic Volume
EDVi	End Diastolic Volume index
TID	Transient Ischemic Dilation



# Adenosine Stress Electrocardiography

Patient Name: <b>Infarct, Example</b>	Referring Physician: <b>Geoff Refman</b>
Date of Study: <b>2010-01-01</b> Inpatient Rm: <b>0001</b>	8700 Beverly Blvd.
ID Number: <b>98700003</b> Acct#: <b>1234567890123</b>	NT LL A047
Age: <b>67</b> Sex: <b>M</b> DOB: <b>1943-01-01</b>	Los Angeles, CA, 90048
	Fax (310) 555-2233 Phone (310) 555-1234

A total of 55.3 mg of Adenosine was infused. A standard 12 LEAD ELECTROCARDIOGRAM was recorded in the supine position with continuous ECG monitoring throughout infusion and recovery. Additionally, 12 LEAD ELECTROCARDIOGRAMS were recorded every minute.

### Adenosine Physiology

Resting Hemodynamics	<b>Heart Rate: 60</b> <b>Blood Pressure: 96/63</b>
Arrhythmia	None

Stress							Recovery		
Minutes	HR	BP	MPH	Grade	METS	Comments	HR	BP	Comments
1	60						60		
2	60	123/62				chest discomfort	60	88/54	symptoms resolved
3	60						60		
4	63	91/51					60	102/52	
5	66						60		

### Electrocardiogram

<b>Rest</b>	paced atrial rhythm
<b>Stress</b>	
V5	<b>Maximum Abnormality: None</b>
AVF	<b>Maximum Abnormality: None</b>

Date of study	Stress	Duration	Peak HR	Clinical	ECG
2010-01-01	Adenosine	06:15	66(43 %)	Equivocal	Nondiagnostic (Paced)
2007-09-25	Adenosine		98(63 %)	Nondiagnostic	Nondiagnostic (Paced)

### Impression

Clinical response to Adenosine: Equivocal with chest discomfort  
ECG response to Adenosine: Nondiagnostic due to Paced Rhythm  
Stress ECG monitored and interpreted by Geoff Refman

Sean Hayes, M.D.